

# Clinical utility of Endofaster® in patients on chronic PPI therapy undergoing upper GI endoscopy

R. Cayado-Lopez<sup>1</sup>, J. Bornschein<sup>2</sup>, S. Zeki<sup>2</sup>, M. Udarbe<sup>1</sup>, M. Di Pietro<sup>2</sup>

<sup>1</sup> NIHR/Wellcome Trust Clinical Research Facility, Cambridge University Hospitals, Cambridge, UK

<sup>2</sup> MRC Cancer Unit, University of Cambridge, Cambridge, UK



## 1. Background and Aims

1. Patients undergoing OGD for dyspepsia or GORD are often on PPI, which can affect the result of rapid urease (CLO) test for H. Pylori (H.p.)
2. Approximately 30% of patients on PPI for reflux disease have incomplete symptomatic response
3. Gastro-oesophageal reflux can be sub-clinical, as suggested by the absence of reflux history in up to 40% of patients with oesophageal adenocarcinoma

Endofaster® is an endoscopic adjunct which analyzes gastric juice for pH and H.p. contamination, providing real-time result during OGD. Patient are normally advised to stop PPI prior to the procedure. We have conducted a pilot study to understand the potential clinical utility of Endofaster® in patients on chronic PPI treatment

## 2. Methods

175 consecutive patients were recruited for this study. Patients demographics are showed in table 1. All patients underwent OGD, during which analysis of the gastric juice was performed by Endofaster®. Endofaster® stands between the endoscopy stack and the suction system (Figure 1) and receives the gastric juice that is routinely aspirated through the endoscope. Endofaster® measures pH and the concentration of ammonium, which correlates with the presence of H. pylori. pH <4 was regarded as acidic in keeping with pH metry threshold. Ammonium >70ppm indicated H. pylori positivity. CLO test and gastric biopsies were performed if clinically indicated.

H.p. was detected by immunohistochemistry. History of PPI therapy was noted and last dose of PPI before the OGD was recorded.

Figure 1

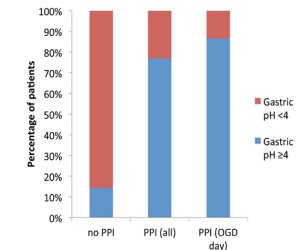


Table 1

Demographics	n=175
Median age [range]	66 [21-86]
Sex (M:F)	2.4 : 1
Indication to OGD	
Barrett's surveillance	78%
Evaluation of GORD	15%
Family history of UGI cancer	7%
PPI status	
No PPI	28
Chronic PPI (at least 1 month prior to OGD)	147
PPI taken on the day of OGD	82
H. Pylori	
Patients with positive at CLO/total who had CLO	3/67
Patients with evidence of H.p. on biopsies/total patients with gastric histology available	1/63

## 3. Results (I)

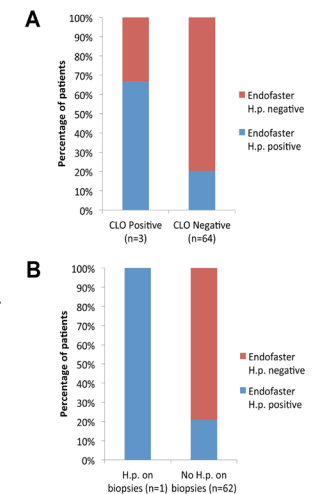
Figure 2. 147 patients were on chronic PPI therapy at the time of the endoscopy. Of these, 23.1% had acidic pH (<4) (Figure 2). To exclude patients with rebound acid-secretion due to missed doses, we looked at patient who had a PPI dose on the day of the OGD (PPI OGD day, n=82) and found that 13.4% had acid gastric pH, suggesting ineffective control of gastric acidity by PPI



## 4. Results (II)

Figure 3 A. 67 patients had CLO test performed during the OGD. Only 3 of them tested positive. Of these, 2 had positive Endofaster® test for H.p. Of the remaining 64, 13 had positive Endofaster® test for H.p. All the patients with positive Endofaster for H.p., but one, were on PPI.

Figure 3 B. 63 patients had gastric biopsies taken during the OGD. Only one patient had H. P. found on immunohistochemistry, and this was also positive at Endofaster®. 13 out of 62 patients without histologic evidence of H. Pylori had positive Endofaster® test for H. pylori.



## 5. Conclusions

- A significant proportion of patients on PPI has an partial suppression of gastric acidity and potentially has sub-optimal response to PPI. This could have significant implications for patients with Barrett's.
- Endofaster® may detect H.p contamination in patient on PPI therapy where other tests, such as CLO test and histology, may be falsely negative due to heterogeneous gastric distribution of the bacterium
- These results need confirmation using gold standard tests (pH metry and faecal/breath test off PPI)